IV CURSO DE HEPATOLOGÍA
DE LA ASOCIACIÓN CHILENA DE HEPATOLOGÍA
"Preguntas clínicas frecuentes en la práctica clínica"

Paciente sano con lesión focal hepática en ecografía. ¿Qué puede ser, cómo puedo precisar el diagnóstico?

Dr. Giancarlo Schiappacasse F.
Facultad de Medicina Clínica Alemana – UDD
HOSMIL / Red Salud Providencia

¿EL PROBLEMA?

- Se pueden encontrar lesiones focales hepáticas (LFH) hasta en un 30% de las personas mayores de 40 años
- Las mayor parte de ellas son descubiertas en forma incidental (incidentaloma) y son asintomáticas
- En situación post-mortem hasta un 52% de las personas sin antecedentes oncológicos presentan lesiones hepáticas

INCIDENTALOMA

Lesión asintomática encontrada en un examen por una causa no relacionada o en un tamizaje de otra patología

LESIONES ANECOICAS

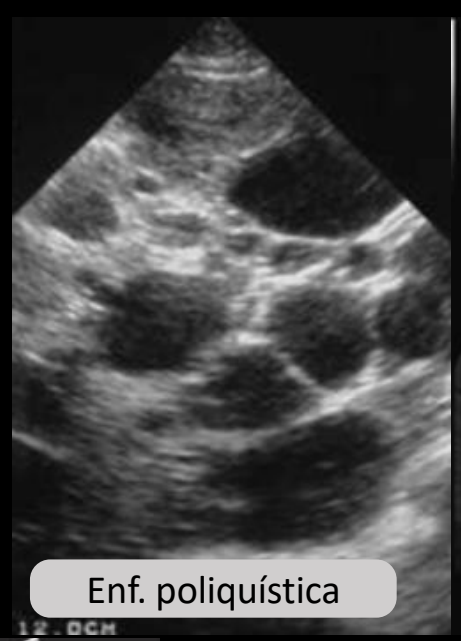

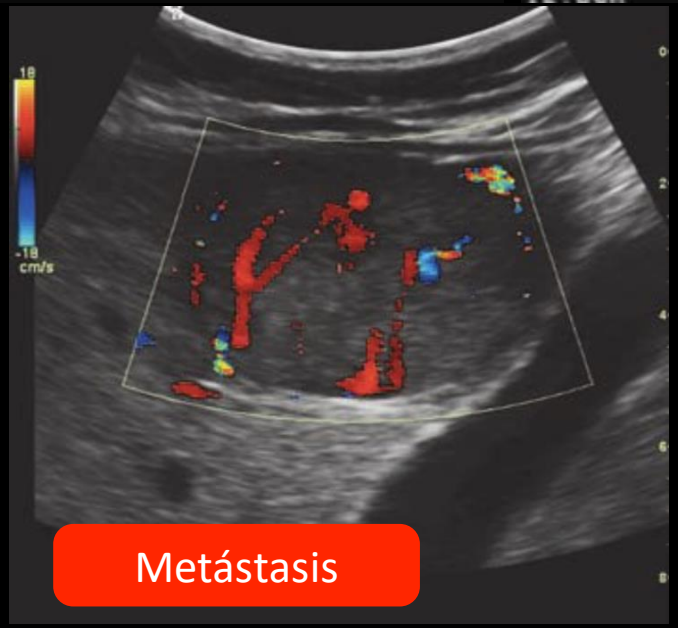

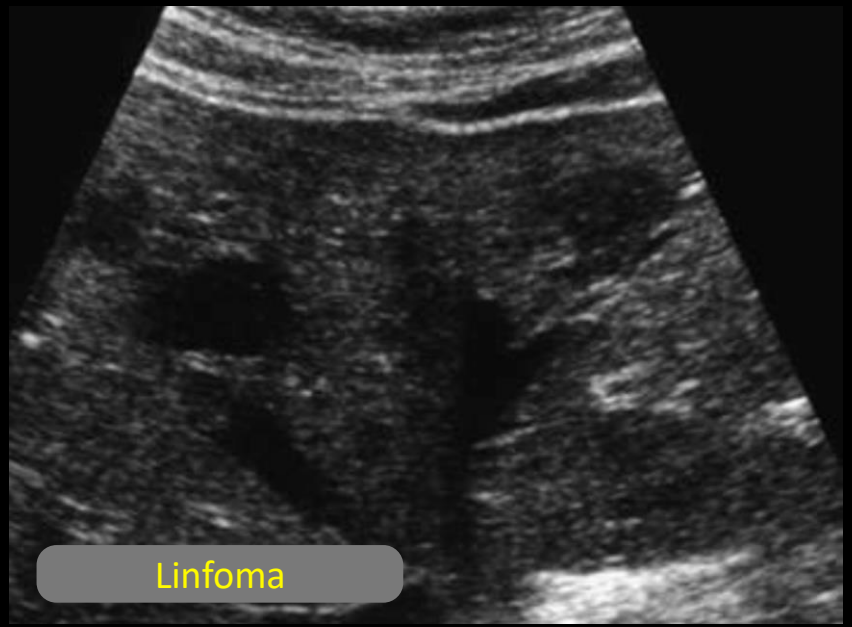

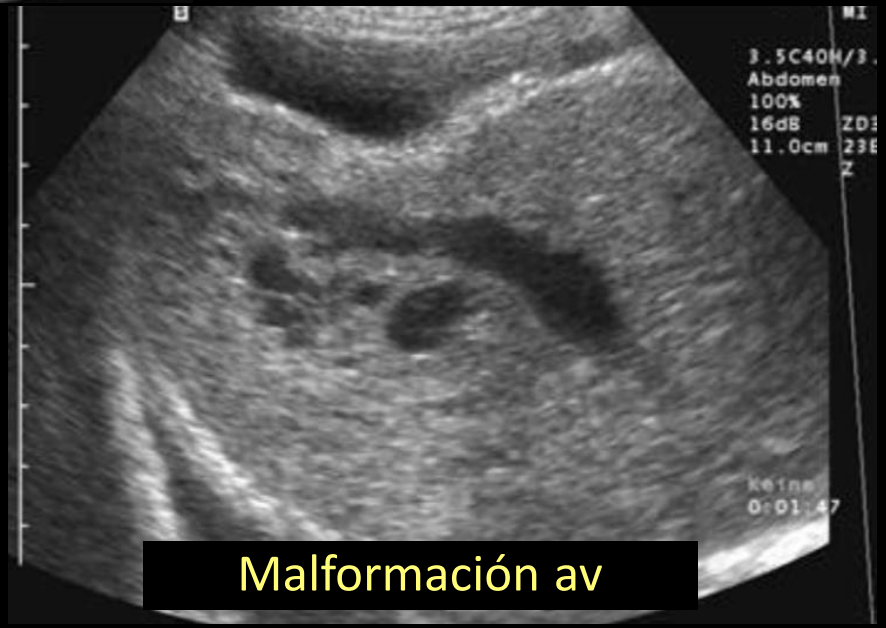

LESIONES HIPOECOICAS

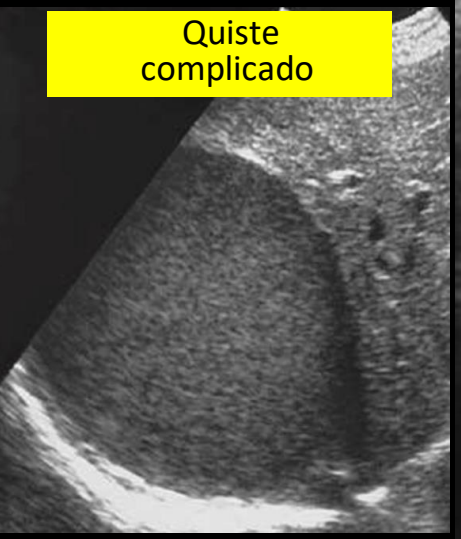

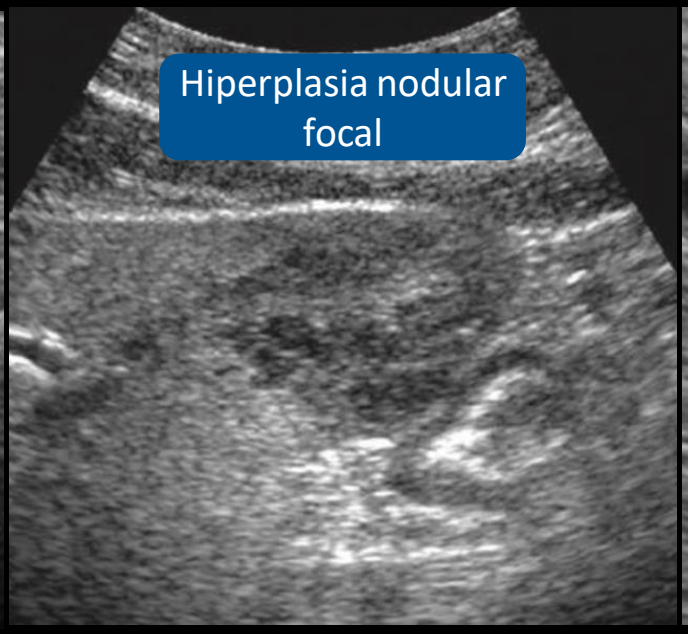

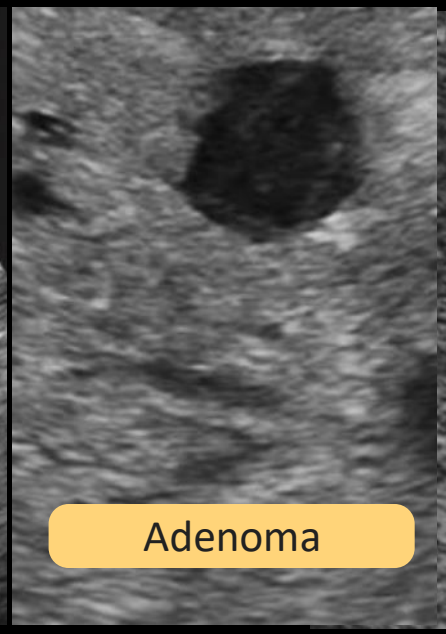

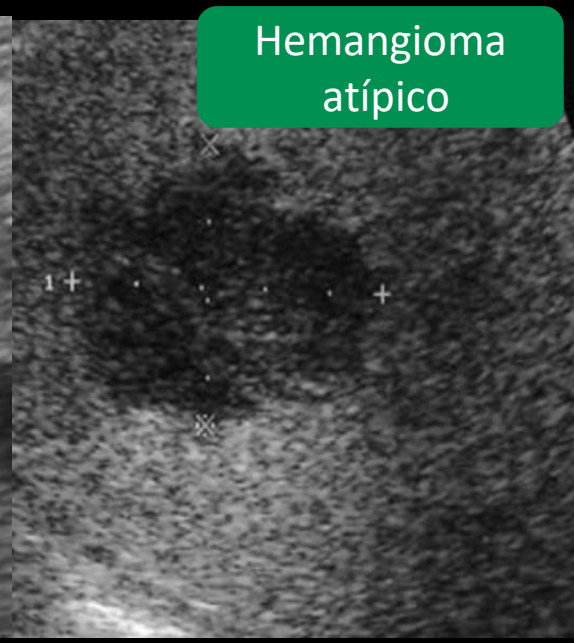

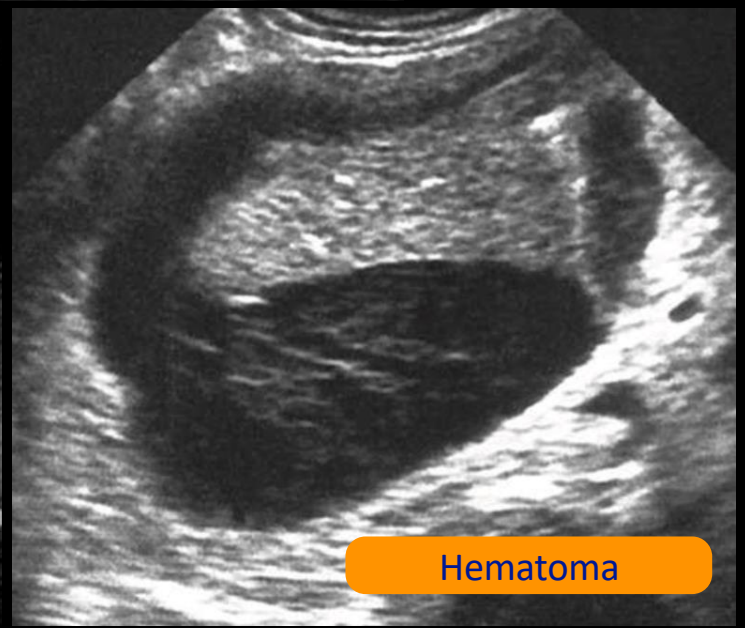

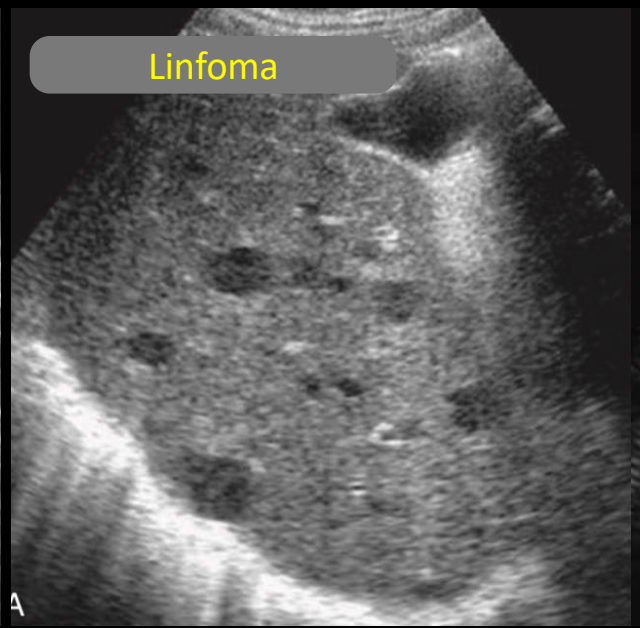

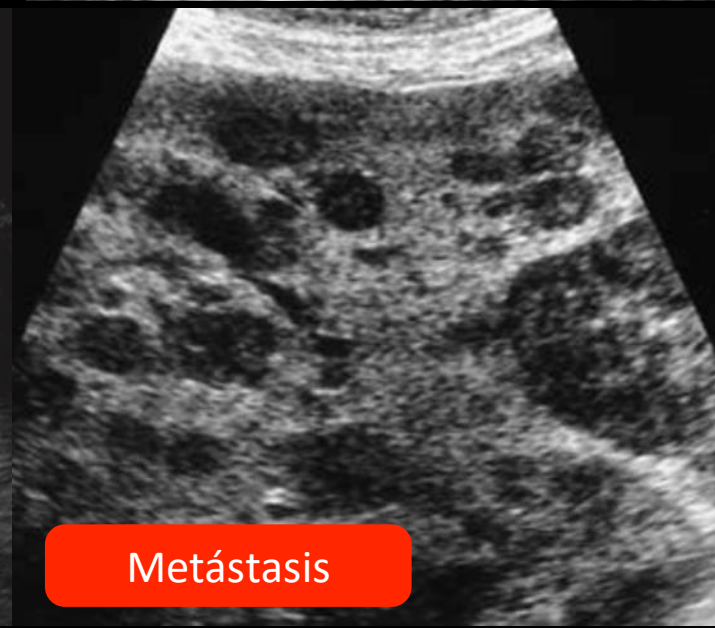

LESIONES ISOECOICAS

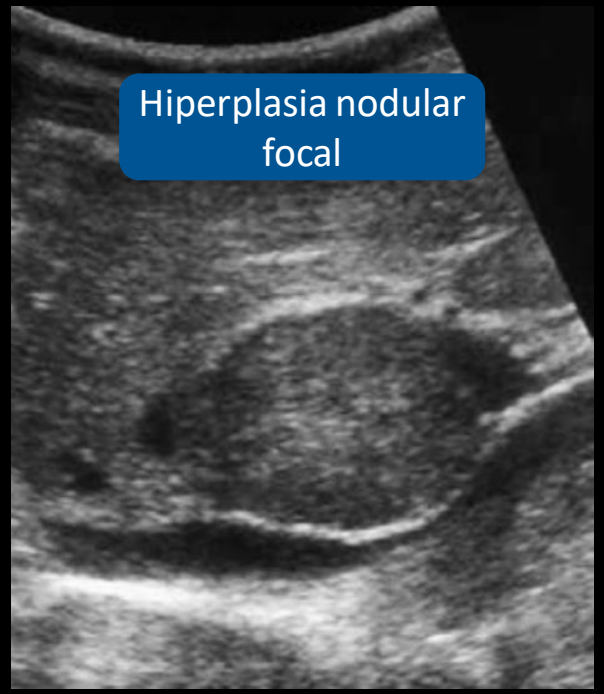

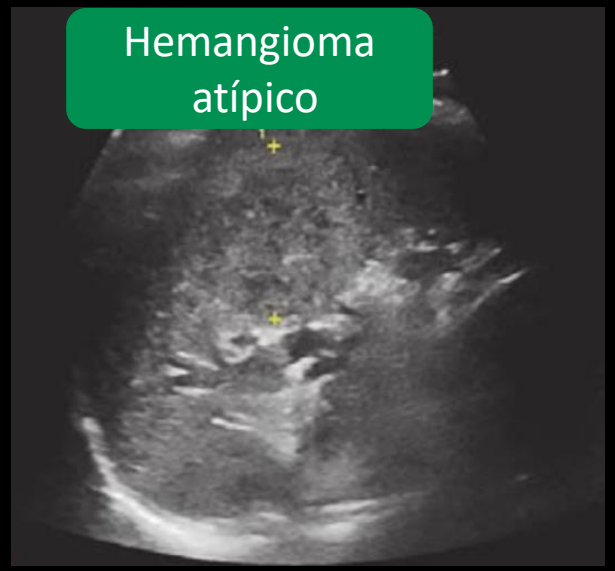

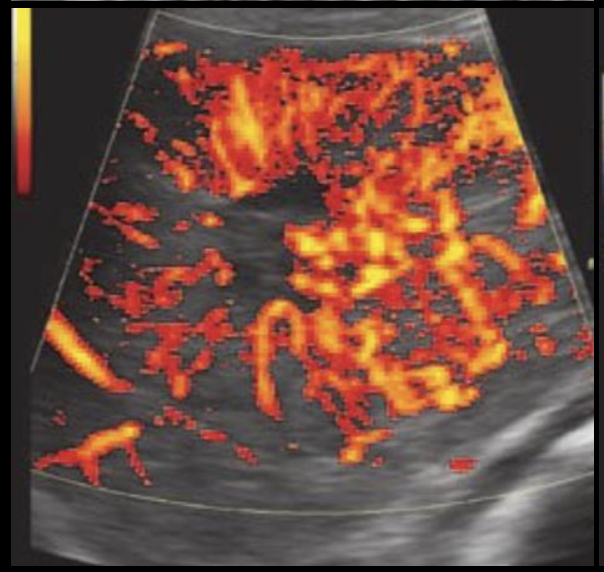

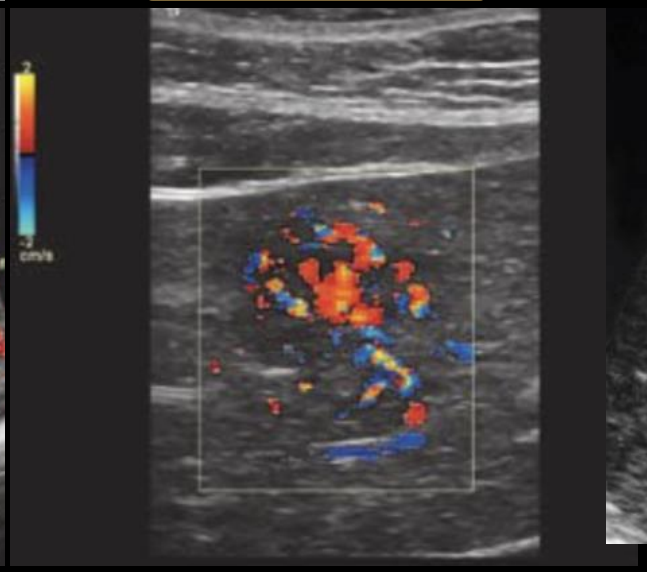

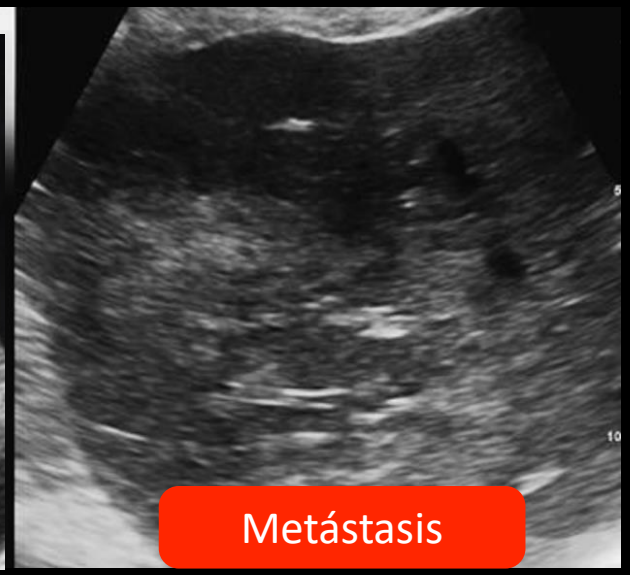

LESIONES HIPERECOICAS

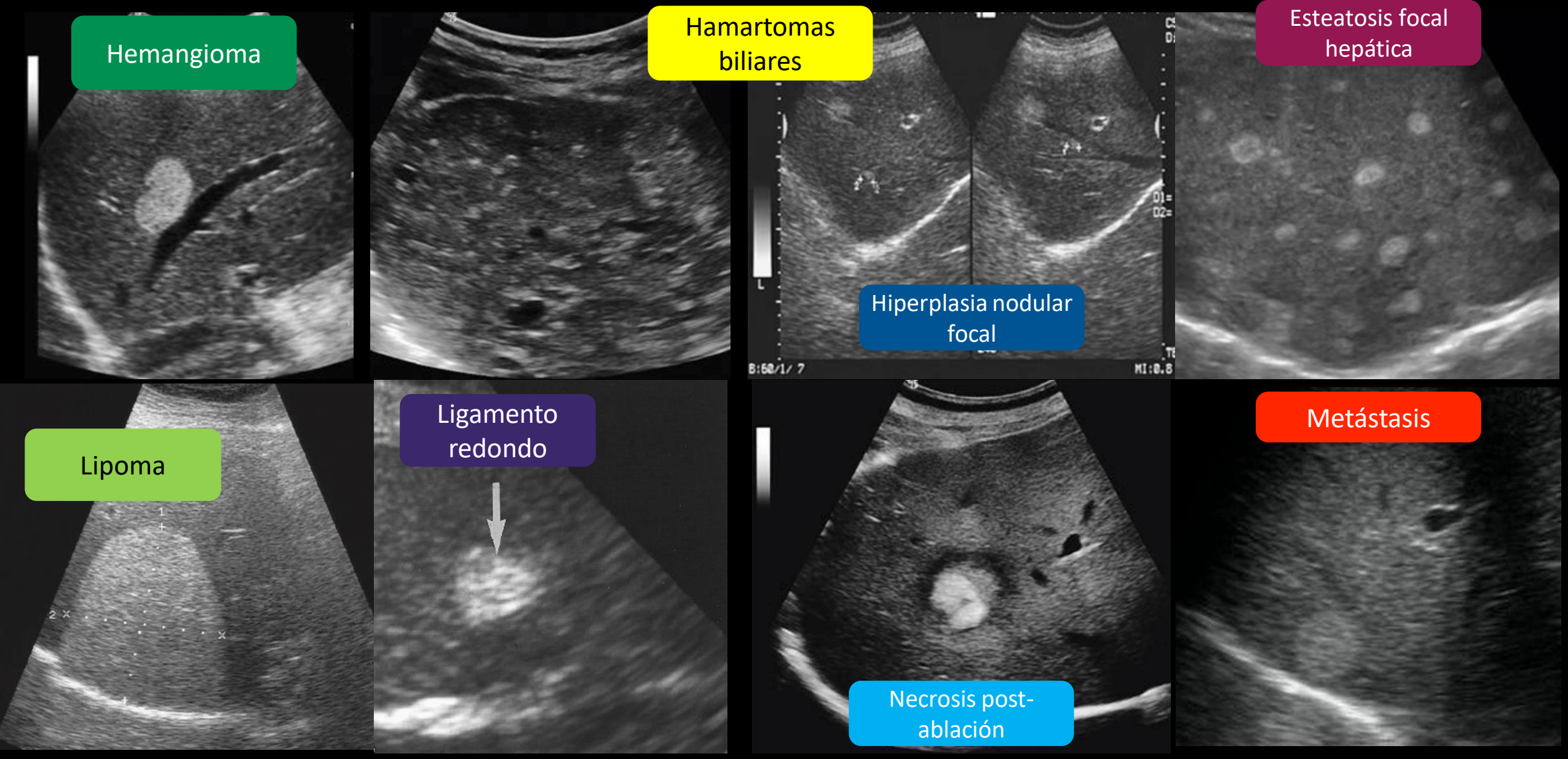

TRES ESCENARIOS CLÍNICOS

- **SANO**
- **HEPATOPATÍA CRÓNICA**
- **ONCOLÓGICO**

ESCENARIOS CLÍNICOS

- > 60 años:
  - Quiste, metástasis, HCC
- > 50 años:
  - Quiste, hemangioma, metástasis
- > 40 años:
  - Hiperplasia nodular focal
- > 30 años:
  - Adenoma hepático

ESCENARIOS CLÍNICOS

- Asintomático:
  - Hemangioma
  - Quiste
  - Hiperplasia Nodular Focal
- Sintomático:
  - Absceso
  - Hepatocarcinoma
  - Adenoma
  - Metástasis

ESCENARIOS CLÍNICOS

♀ Predominio femenino:

- Adenoma (casi siempre)
- Hiperplasia nodular focal (gran predominio)
- Hemangioma (ligero predominio)

♂ Predominio masculino:

- HCC
- Absceso

ACR Appropriateness Criteria

The ACR Appropriateness Criteria® (AC) are evidence-based guidelines to assist referring physicians and other providers in making the most appropriate imaging or treatment decision for a specific clinical condition. Employing these guidelines helps providers enhance quality of care and contribute to the most efficacious use of radiology. Learn more »

The newest ACR AC are listed below.

See the complete list of ACR AC topics and ratings tables »

Browse Topics

https://www.acr.org/Clinical-Resources/ACR-Appropriateness-Criteria

Clinical Condition: **Liver Lesion—Initial Characterization**

Variant 1: **Indeterminate >1 cm lesion on initial imaging with ultrasound. Normal liver. (No suspicion or evidence of extrahepatic malignancy or underlying liver disease.)**

Radiologic Procedure	Rating	Comments	RRL*
MRI abdomen without and with IV contrast	8	MRI is the best test for characterizing liver lesions.	O
CT abdomen without and with IV contrast	7	Consider this procedure if the lesion is not cystic on US and MRI is not available or contraindicated.	☢☢☢☢
CT abdomen with IV contrast	7	Consider this procedure if the lesion is not cystic on US and MRI is not available or contraindicated.	☢☢☢
MRI abdomen without IV contrast	6	Consider this procedure if MRI with gadolinium is contraindicated.	O
Percutaneous image-guided biopsy liver	5	Consider this procedure if imaging findings are atypical, inconclusive, or suspicious for malignancy after doing contrast-enhanced CT or MRI.	Varies
CT abdomen without IV contrast	3	Consider this procedure if there is a contraindication to MRI and CT contrast agents.	☢☢☢
Tc-99m sulfur colloid scan liver	3	Consider this procedure to evaluate for FNH if GFR precludes CT or MRI contrast agents.	☢☢☢
Tc-99m RBC scan liver	3	Consider this procedure if a hemangioma is suspected and if GFR precludes CT or MRI contrast agents.	☢☢☢
In-111 somatostatin receptor scintigraphy	3	This procedure is not appropriate unless there is a known or suspected neuroendocrine tumor.	☢☢☢☢
FDG-PET/CT whole body	3	This procedure is not appropriate unless there is a known malignancy.	☢☢☢☢

Rating Scale: **1,2,3 Usually not appropriate; 4,5,6 May be appropriate; 7,8,9 Usually appropriate**

***Relative Radiation Level**

Variant 1: Indeterminate >1 cm lesion on initial imaging with ultrasound. Normal liver. (No suspicion or evidence of extrahepatic malignancy or underlying liver disease.)

Procedure	Appropriateness Category	SOE	Adult RRL	Peds RRL	Rating	Median	Final Tabulations								
							1	2	3	4	5	6	7	8	9
MRI abdomen without and with IV contrast	Usually appropriate		O 0 mSv	O 0 mSv [ped]	8	n/a	0	0	0	0	0	0	0	0	0
CT abdomen with IV contrast	Usually appropriate		☢☢☢ 1-10 mSv	☢☢☢☢ 3-10 mSv [ped]	7	n/a	0	0	0	0	0	0	0	0	0
CT abdomen without and with IV contrast	Usually appropriate		☢☢☢☢ 10-30 mSv	☢☢☢☢☢ 10-30 mSv [ped]	7	n/a	0	0	0	0	0	0	0	0	0
MRI abdomen without IV contrast	May be appropriate		O 0 mSv	O 0 mSv [ped]	6	n/a	0	0	0	0	0	0	0	0	0
Percutaneous image-guided biopsy liver	May be appropriate		Varies		5	n/a	0	0	0	0	0	0	0	0	0
Tc-99m RBC scan liver	Usually not appropriate		☢☢☢ 1-10 mSv		3	n/a	0	0	0	0	0	0	0	0	0
In-111 somatostatin receptor scintigraphy	Usually not appropriate		☢☢☢☢ 10-30 mSv		3	n/a	0	0	0	0	0	0	0	0	0
FDG-PET/CT whole body	Usually not appropriate		☢☢☢☢ 10-30 mSv		3	n/a	0	0	0	0	0	0	0	0	0
CT abdomen without IV contrast	Usually not appropriate		☢☢☢ 1-10 mSv	☢☢☢☢ 3-10 mSv [ped]	3	n/a	0	0	0	0	0	0	0	0	0
Tc-99m sulfur colloid scan liver	Usually not appropriate		☢☢☢ 1-10 mSv		3	n/a	0	0	0	0	0	0	0	0	0

Clinical Condition: **Liver Lesion—Initial Characterization**

Variant 10: **Indeterminate <1 cm lesion on initial imaging with ultrasound. Normal liver. (No suspicion or evidence of extrahepatic malignancy or underlying liver disease.)**

Radiologic Procedure	Rating	Comments	RRL*
MRI abdomen without and with IV contrast	8		O
CT abdomen without and with IV contrast	7	Consider this procedure if the lesion is not cystic on US and MRI is not available or contraindicated.	☢☢☢☢
MRI abdomen without IV contrast	6	Consider this procedure if MRI with gadolinium is contraindicated.	O
CT abdomen with IV contrast	6	Consider this procedure if the lesion is not cystic on US and MRI is not available or contraindicated.	☢☢☢
CT abdomen without IV contrast	3	Consider this procedure if there is a contraindication to MRI and CT contrast agents.	☢☢☢
Percutaneous image-guided biopsy liver	3	Consider this procedure if imaging findings are atypical, inconclusive, or suspicious for malignancy after performing CT or MRI with contrast. However, there may be challenges when attempting to biopsy small lesions.	Varies
Tc-99m sulfur colloid scan liver	3	Consider this procedure to evaluate for FNH if GFR precludes CT or MRI with contrast.	☢☢☢
Tc-99m RBC scan liver	3	Consider this procedure if a hemangioma is suspected and if GFR precludes CT or MRI with contrast.	☢☢☢
FDG-PET/CT whole body	3	This procedure is not appropriate unless there is a known malignancy.	☢☢☢☢
In-111 somatostatin receptor scintigraphy	2	This procedure is not appropriate unless there is a known or suspected neuroendocrine tumor.	☢☢☢☢

Rating Scale: **1,2,3 Usually not appropriate; 4,5,6 May be appropriate; 7,8,9 Usually appropriate**

***Relative Radiation Level**

Variant 10: Indeterminate <1 cm lesion on initial imaging with ultrasound. Normal liver. (No suspicion or evidence of extrahepatic malignancy or underlying liver disease.)

Procedure	Appropriateness Category	SOE	Adult RRL	Peds RRL	Rating	Median	Final Tabulations								
							1	2	3	4	5	6	7	8	9
MRI abdomen without and with IV contrast	Usually appropriate		O 0 mSv	O 0 mSv [ped]	8	n/a	0	0	0	0	0	0	0	0	0
CT abdomen with IV contrast	May be appropriate		☢☢☢ 1-10 mSv	☢☢☢☢ 3-10 mSv [ped]	6	n/a	0	0	0	0	0	0	0	0	0
CT abdomen without and with IV contrast	Usually appropriate		☢☢☢☢ 10-30 mSv	☢☢☢☢☢ 10-30 mSv [ped]	7	n/a	0	0	0	0	0	0	0	0	0
MRI abdomen without IV contrast	May be appropriate		O 0 mSv	O 0 mSv [ped]	6	n/a	0	0	0	0	0	0	0	0	0
Percutaneous image-guided biopsy liver	Usually not appropriate		Varies		3	n/a	0	0	0	0	0	0	0	0	0
FDG-PET/CT whole body	Usually not appropriate		☢☢☢☢ 10-30 mSv		3	n/a	0	0	0	0	0	0	0	0	0
CT abdomen without IV contrast	Usually not appropriate		☢☢☢ 1-10 mSv	☢☢☢☢ 3-10 mSv [ped]	3	n/a	0	0	0	0	0	0	0	0	0
Tc-99m sulfur colloid scan liver	Usually not appropriate		☢☢☢ 1-10 mSv		3	n/a	0	0	0	0	0	0	0	0	0
Tc-99m RBC scan liver	Usually not appropriate		☢☢☢ 1-10 mSv		3	n/a	0	0	0	0	0	0	0	0	0
In-111 somatostatin receptor scintigraphy	Usually not appropriate		☢☢☢☢ 10-30 mSv		2	n/a	0	0	0	0	0	0	0	0	0

Appendix 1.

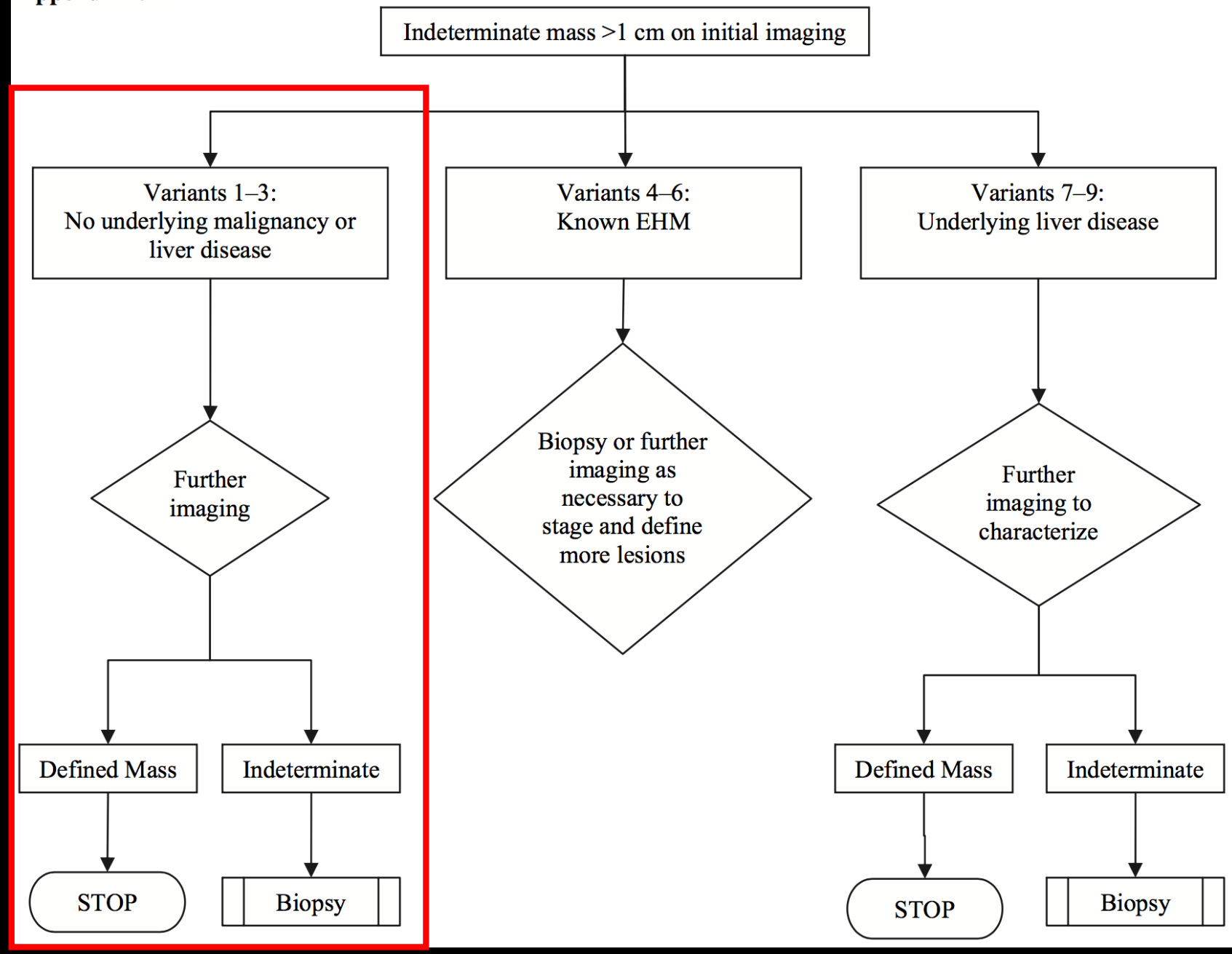
Indeterminate mass >1 cm on initial imaging
Variants 1–3:
No underlying malignancy or liver disease
Variants 4–6:
Known EHM
Variants 7–9:
Underlying liver disease
Further imaging
Biopsy or further imaging as necessary to stage and define more lesions
Further imaging to characterize
Defined Mass
Indeterminate
Defined Mass
Indeterminate
STOP
Biopsy
STOP
Biopsy

Appendix 2.

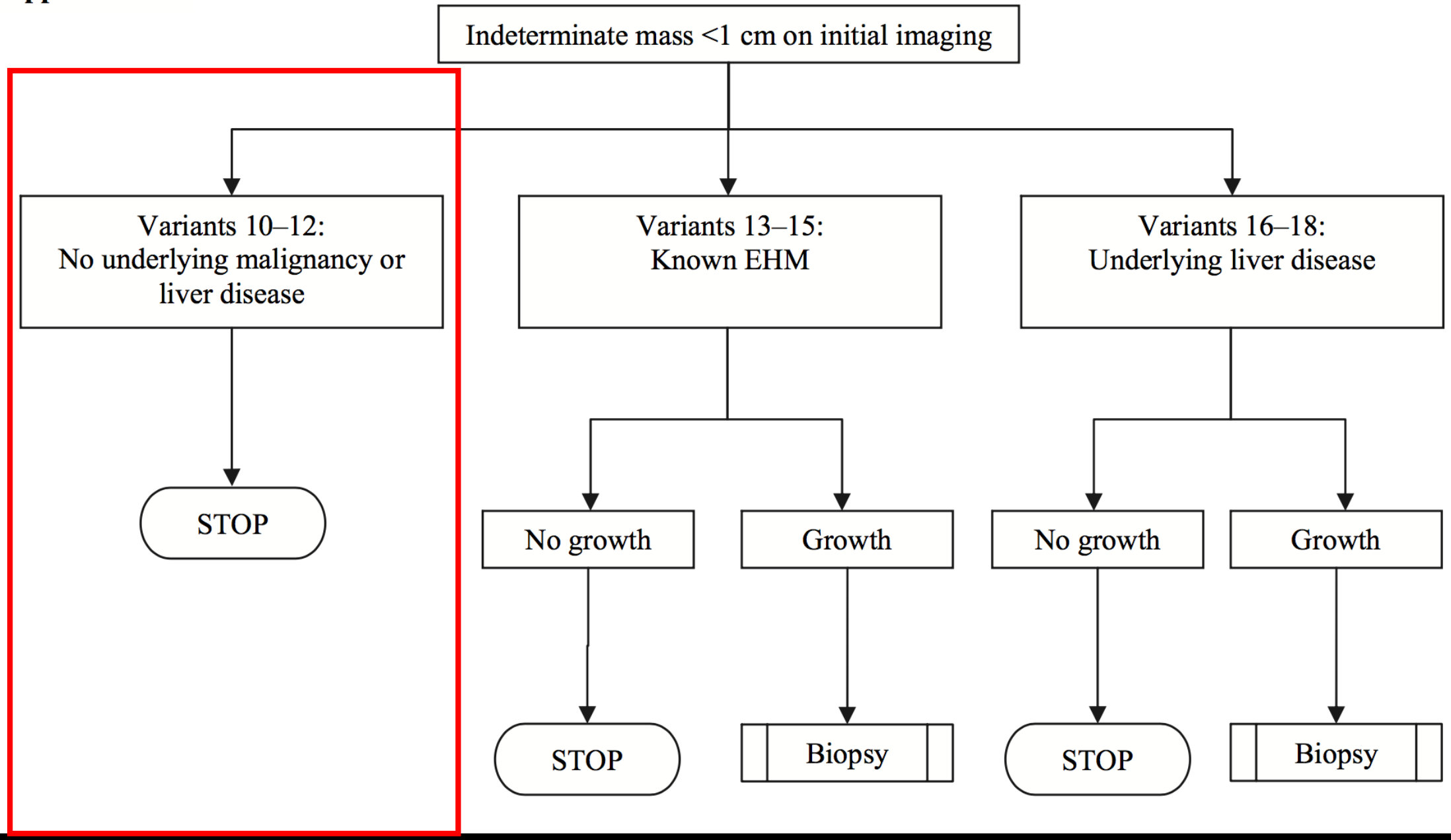
Indeterminate mass <1 cm on initial imaging
Variants 10–12:
No underlying malignancy or liver disease
Variants 13–15:
Known EHM
Variants 16–18:
Underlying liver disease
STOP
No growth
Growth
No growth
Growth
STOP
Biopsy
STOP
Biopsy

ACG Clinical Guideline: The Diagnosis and Management of Focal Liver Lesions

Jorge A. Marrero, MD[1], Joseph Ahn, MD, FACG[2] and K. Rajender Reddy, MD, FACG[3] on behalf of the Practice Parameters Committee of the American College of Gastroenterology

Focal liver lesions (FLL) have been a common reason for consultation faced by gastroenterologists and hepatologists. The increasing and widespread use of imaging studies has led to an increase in detection of incidental FLL. It is important to consider not only malignant liver lesions, but also benign solid and cystic liver lesions such as hemangioma, focal nodular hyperplasia, hepatocellular adenoma, and hepatic cysts, in the differential diagnosis. In this ACG practice guideline, the authors provide an evidence-based approach to the diagnosis and management of FLL.

Am J Gastroenterol 2014; 109:1328–1347; doi:10.1038/ajg.2014.213; published online 19 August 2014

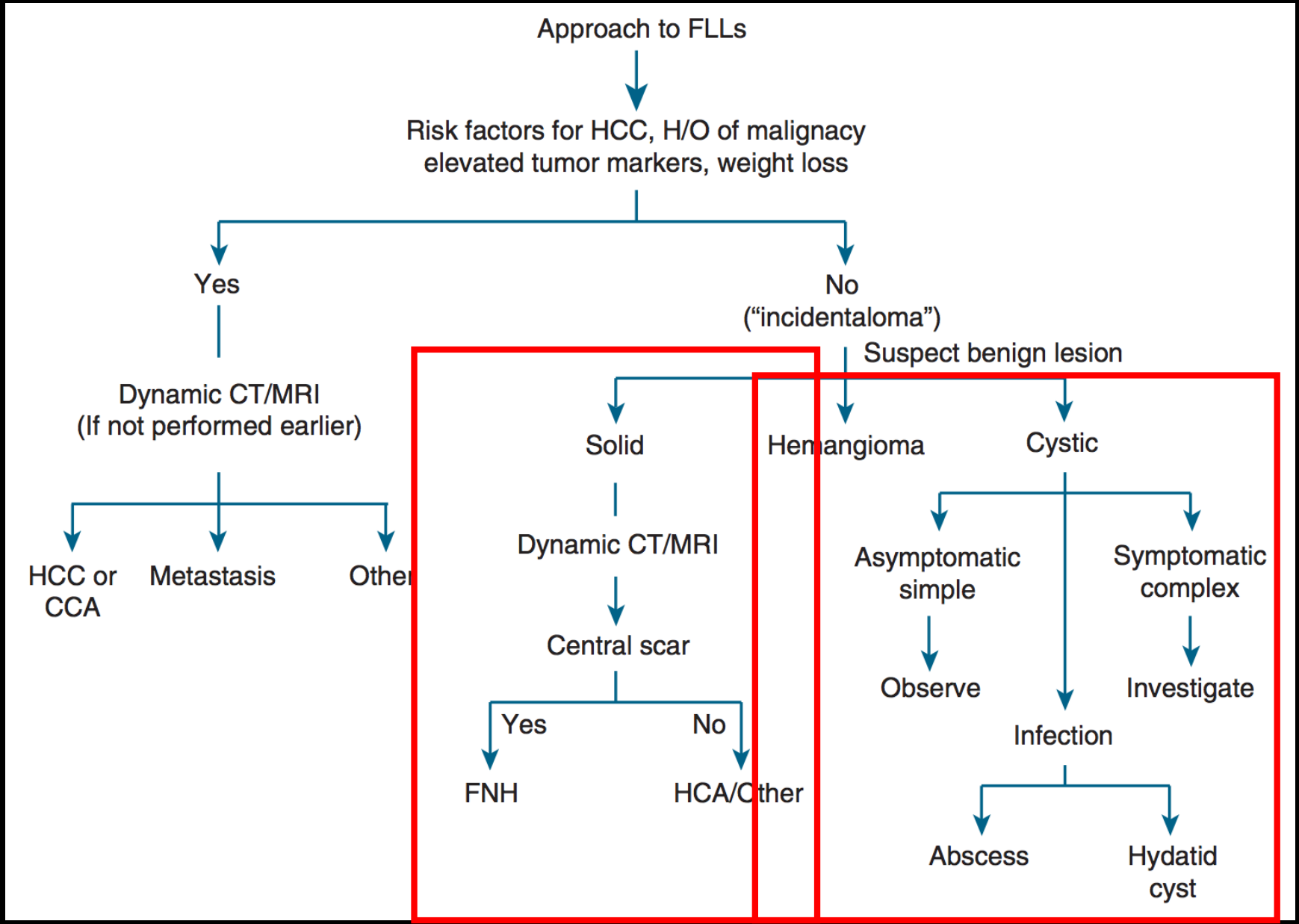
Approach to FLLs
Risk factors for HCC, H/O of malignacy
elevated tumor markers, weight loss
Yes
No
("incidentaloma")
Dynamic CT/MRI
(If not performed earlier)
HCC or
CCA
Metastasis
Other
Suspect benign lesion
Solid
Hemangioma
Cystic
Dynamic CT/MRI
Central scar
Yes
No
FNH
HCA/Other
Asymptomatic
simple
Observe
Symptomatic
complex
Investigate
Infection
Abscess
Hydatid
cyst

EN MI OPINIÓN PERSONAL
EN PACIENTE SANO

- ✓**Lesión de < 1 cm:** no es necesario habitualmente complementar con otras modalidades de imagen. **Excepción: lesiones múltiples**

- ✓**Lesión de > 1 cm:** Si son lesiones características como **quistes o hemangiomas** no sería necesario exámenes complementarios. El resto de las ellas podrían ser estudiadas en forma complementaria dependiendo de antedecentes, factores del pacientes, etc.

EN RESUMEN

- ✓ Los factores clínicos pueden ayudar a determinar la causa de las LFH: incluidos la edad, sexo, uso de ACO, etc.

- ✓ El tamaño de la LFH es crucial para guiar el trabajo, ya que los menores de 1 cm son generalmente hallazgos incidentales benignos.

Muchas gracias